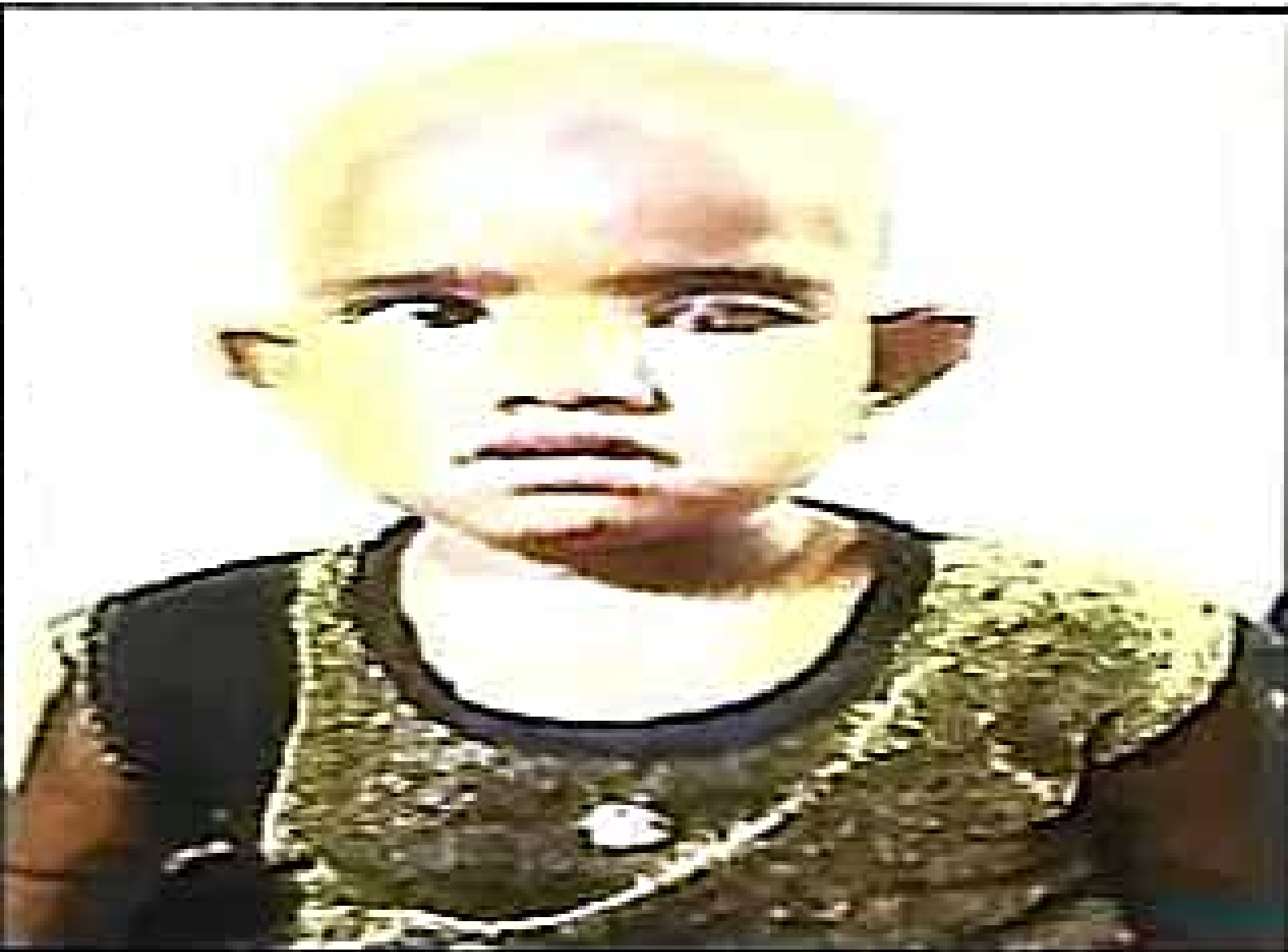



All India Institute of Medical Sciences, New Delhi.

Division of pediatric Oncology

TREATMENT PROTOCOL FOR RETINOBLASTOMA

Name Roshni Father's name Noufal Age 3y Sex F POC NO.....family history NO

Squint/white reflex/diminishes vision/red eye/watering of eyes/Proptosis
Others.....

Unilateral/bilateral.....

MT Neg HBsAg Neg HIV Neg

L Intraocular/Extraocular

R Intraocular/Extraocular



Group Metastatic/Non metastatic

Group Metastatic/Non metastatic

Baseline workup/Investigations

USG large mass in vitreous cavity, non visualised margin & RCD in Lt eye.

EUA.....

Indirect Ophthalmoscopy

.....

CT/MRI date & report

(R) multifocal intraocular RB
(L) Extraocular RB

Review of imaging at radioconference Yes/No

NRC

Hb.....TLC.....Platelet.....ANC.....

SGOT/SGPT/S.Bil/SAP.....

MT..... HBsAg.....HIV.....

डॉ. राजेन्द्र प्रसाद नेत्र विज्ञान केन्द्र / Dr. Rajendra Prasad Centre for Ophthalmic Sciences
अखिल भारतीय आयुर्विज्ञान संस्थान/ALL INDIA INSTITUTE OF MEDICAL SCIENCES
एन.एम.आर. विभाग / DEPARTMENT OF N.M.R.

नैदानिक एम. आर.आई. प्रपत्र / CLINICAL MRI REQUISITION FORM

1 Clinical Dept. or Unit RPC, VI Date of Requisition 24/07/28
OPD No. 106663953 CR No. _____ Ward / Bed No. _____

2 Screening Dept. : Radio-diagnosis Neuro-Radiology Cardiac Radiology
(Tick as appropriate)

3 रोगी का नाम /Patient's Name Rashmi आयु / Age 34/12 लिंग / Sex _____
(साफ अक्षरों में / In Block letters)

जन्म तिथि /Date of Birth : दिन /Day _____ माह /Month _____ वर्ष /Year _____ वजन /Weight _____ कि. ग्र. /kg.

4 General Patient Condition (Tick as appropriate)
(i) Critical and with life support (ii) Ill but without life support (iii) Ambulatory

5 Clinical Details : History : (R) Group C RB
(L) EORB (chemoreduced) - Atypical eye

Examinations:

Relevant Investigations :

Previous CT / MR / Other Reports / Studies

(with numbers, if any)

(R) Group C RB. (L) EORB chemoreduced

6 Clinical Diagnosis : _____

7 Exact Anatomical site for MRI : MRI Brain + Orbit contrast enhanced Fat suppressed axial, sagittal, coronal sections 2mm section

8. Special Instructions (Sedation, Allergy or other details which may facilitate a safe and informative study). through optic nrv & Axial glan

10. (a) Contrast Enhancement Required : Yes _____ No _____

(b) Implant in Body (Tick as appropriate)

Cardiac Pacemaker _____ Aneurysmal clips _____ Cardiac Valve/Prosthesis _____

Metallic Implants _____ Sharpnel/Pellet _____ Others _____ None _____

(114) M&O kindly
ultr for
MR
report. M

हस्ताक्षर / Signature _____
नाम / Name _____
साफ अक्षरों में / In Block letters
पदनाम / Designation _____

(Requisition may be signed by a Faculty Member/Sr. Resident)



अभिनव भारतीय आयुर्विज्ञान संस्थान, नई दिल्ली
All India Institute Of Medical Sciences, New Delhi

UID:	20250915	Sex:	Female
Patient Name:	Miss RANJINI RANJANI	Sample Received Date:	18-Sep-2023 10:09 PM
Age:	76 year	Department:	Pathology
Lab Name:	Diagn. Lab. (Biochem.) Medicine	Lab Sub Centre:	Senior Lab. Sec. OPD Block
Reg. Date:	18-Sep-2023 10:09 PM	Sample Collection Date:	18-Sep-2023 13:44 PM
Recommeneded By:	Dr. S. K. KAPUR	Lab Reference No:	2712942690
Sample Details: E10309251451		Sample Type: Whole Blood	

Report

HEMATOLOGY

Test Name	Result	UOM	Reference
Hb	9.30	g/dl	11.0 - 14.0
Hematocrit	30.60	%	34 - 40
RBC count	3.37	10 ⁶ /µL	4.0 - 5.2
WBC count	5.49	10 ³ /µl	5.0 - 15.0
Platelet count	309.00	10 ³ /µl	200 - 400
MCV	90.80	fL	75 - 87
MCH	37.00	pg	24 - 30
MCHC	30.40	g/dl	31 - 37
RDW-CV	26.40	%	11.6 - 14
Neutro	37.90	%	50-60%
Lympha	46.40	%	20-65%
Eosino	0.00	%	1-1%
Mono	15.50	%	2-10%
NRRR	1	%	
Baso	0.20	%	0-1%
Neutro - Abs	2.08	10 ³ /µL	1.5-8.0
Lymphs - Abs	2.55	10 ³ /µL	6.0-9.0
Eosino - Abs	0.00	10 ³ /µL	0.1 - 1.0
Mono - Abs	0.85	10 ³ /µL	0.2 - 1.0
Baso - Abs	0.01	10 ³ /µL	0.02 - 0.1

---End of Report---

Dr. Neelaj Kumar Datta
(Biochemistry & Immunoserology)

Dr. Tushar Sehgal
(Hematology & Coagulation)

Dr. Sonceeta Meena
(Serology)

Dr. Kamal Kumar MD (Lab
Medicine)
18-Sep-2023 18:48

Attention: Please do not discard samples by puncturing the rubber cap of the vacutainers. Manual opening of caps and filling of used by
reusing the cap may lead to potential biological errors due to inappropriate patient pretreatment, phlebotomy practices, laboratory
contamination, etc. For more information, visit www.nimh.ac.in or contact our show-rooms with the expected result on the same day on 011-2619 2579

ब० रो० वि० कार्ड
O.P.D. Card

डा० राजेन्द्र प्रसाद नेत्र विज्ञान केन्द्र
अ० भा० आयु० सं०, नई दिल्ली - 110029

Dr. Rajendra Prasad Centre for Ophthalmic Sciences
A.I.I.M.S., New Delhi-110029

यू०एच०आई०डी० संख्या

UHID No. 106665953



अनुभाग व दिन
Section and Day VI
बुधवार व शनिवार
Wednesday & Saturday

कमरा नंबर
Cabin No.

आचार्य राधिका टंडन का एकक

Prof. Radhika Tandon's Unit

रोगी का नाम Name of the Patient	पुत्र/पुत्री/पत्नी S/D/W	लिंग Sex	आयु Age	पता Address
RASHMI		F	3	

दिनांक DATE	निदान DIAGNOSIS
	(R) Group C RB (L) Chemoreduced RB EORB (Medical Z corneal melt E RD)

7/8/23

उपचार Treatment
NRC Review (MRI films:-27/7/23)
↓ SR Radio

- (L) still Extra-ocular component
- (L) < 1 mm ON involvement
- (R) - No ON involvement.
- ? temporal scleral involvement

Neo-adjvant
- 3 chemo cycle retrieved (last - 30/6/23)
- 1 remaining
- previous MRI films NOT BROUGHT.

Adv:- Need previous MRI films for comparison
- F/U @ previous and current MRI films on Monday ~~at 10:00 AM~~
ward #A @ 8:00 AM.
- continue chemo cycles

[Signature]
Dr. Tannay

कृपया इस कार्ड को सुरक्षित रखें तथा अस्पताल में दिखाने के समय हर वक्त साथ लायें।

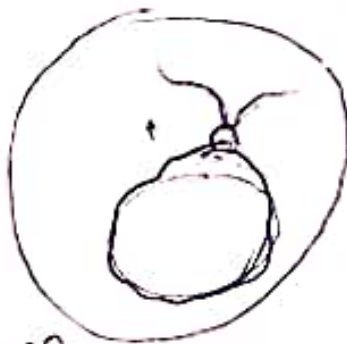
Kindly keep this Card safely and bring it on your follow-up visits.

1. धूम्रपान निषेध
2. कूड़ा कर्कट केवल कूड़ेदान में ही डालें
3. थूकिये नहीं
1. No Smoking
2. Use Dustbin
3. No Spitting

दिनांक - Date

उपचार - Treatment

(R)



USG (R) - (R) Mass in Vitreous
Cavity is Speckle of
Calcification spots

1) Chemoreduced ERB
& Corneal melt is ? (R)
(Hitz)
is phthisis

2) Small globe is mass
involving entire VC
is mass of calcification

3) TTT done - Power 300
Dex 9000
Ibuprofen 50
Lentils 22

Alr. / Eld. HA 2% (2)
4) Eld. Iodol 0.25% (2)
Eld. Ciplox (3)

5) Ciplox (3) x 5 days + stop

Continue 2 more cycles of Chemo Rx →
Next EIA

21/7/2023
at 5th floor 8^{am}

To be planned
for (R) Enucleation

नेत्र ईश्वरीय सर्वश्रेष्ठ उपहार है जिनका मनुष्य जीवन में दान करना परमश्रेष्ठ है।
इनकी पूर्ण रक्षा कीजिए ताकि ये आपकी रक्षा कर सकें।

NFO
Salads 12000
liquids 5000

Eyes are God's most precious gift to man kind and eye donation is the most noble deed.

Take full care of them so that they can take care of you.

ब० रो० वि० कार्ड
O.P.D. Card

डा० राजेन्द्र प्रसाद नेत्र विज्ञान केन्द्र
अ० भा० आयु० सं०, नई दिल्ली - 110029

Dr. Rajendra Prasad Centre for Ophthalmic Sciences
A.I.I.M.S., New Delhi-110029

यू०एच०आई०डी० संख्या
UHID No. 106663958



अनुभाग व दिन Section and Day VI बुधवार व शनिवार Wednesday & Saturday

कमरा नंबर
Cabin No.

आचार्य राधिका टंडन का एकक
Prof. Radhika Tandon's Unit

रोगी का नाम Name of the Patient	पुत्र/पुत्री/पत्नी S/D/W	लिंग Sex	आयु Age	पता Address
Rashmi		F	3y	

दिनांक DATE	निदान DIAGNOSIS
	(R) Group C RB (L) Chemoreduced EORB

09/10/23

उपचार Treatment
Eva L U-6 L Pr Deep / Dr Sanyal
Post 2 cycles of HDVEE for (L) Ananya
(L) EORB
(R) Group C Multifocal RB (active)

→ (L) Eye - Chemoreduced
Extracocular Rb
(phthisical)
with Corneal Melt
with RD

कृपया इस कार्ड को सुरक्षित रखें तथा अस्पताल में दिखाने के समय हर वक्त साथ लायें।

Kindly keep this Card safely and bring it on your follow-up visits.

1. धूम्रपान निषेध
2. कूड़ा कर्कट केवल कूड़ेदान में ही डालें
3. थूकिये नहीं
1. No Smoking
2. Use Dustbin
3. No Spitting



GOYAL MRI & DIAGNOSTIC CENTRE

B-1/12, SAFDARJUNG ENCLAVE, NEW DELHI - 110029
Phone : 011-40771234, 26107559 E-mail : goyalmri@yahoo.com

Dr. Ankur Gadodia
MD (AIIMS), DNB, FRCR

Dr. Pranay R Kapur
MBBS, DNB

BABY RASHMI, 3 YRS / F

UID: 07.23.2602

27.07.2023

M.R. OF THE BRAIN AND ORBITS WITH CONTRAST

Axial T1, DWI and FSE T2 weighted scans of the brain were studied and these were correlated with coronal T2, fat sat T1 & T2 weighted scans including both orbits. Additional T1 weighted axial, coronal & sagittal scans were obtained following administration of contrast (10mL Omniscan) No immediate adverse contrast reaction was noted.

Follow up case of bilateral retinoblastoma, on chemotherapy, showing -

Left phthisis bulbi is seen. Ill-defined mass lesion is seen in the posterior chamber of the left globe displaying hypointense signal on T1 and T2 weighted images. There is subtle heterogeneous enhancement following administration of contrast. Subtle streakiness is seen in the retroocular fat. Left optic nerve is unremarkable.

Focal mass lesions are seen in the posterior chamber of the right globe along the superomedial (5 x 4 mm) and inferomedial (11 x 7 mm) aspect. No extraocular extension is seen.

Right optic nerve is unremarkable.

Cerebral and cerebellar parenchyma is unremarkable. No acute infarct is seen on diffusion weighted images.

Bilateral basal ganglia and thalami are normal in signal intensity.

The corpus callosum and skull base are normal. No midline shift. No acute intracerebral hemorrhage.

Posterior fossa and brainstem are unremarkable. Skull base arteries demonstrate normal flow void.


Paranasal sinuses are unremarkable.

IMPRESSION:

1. Left phthisis bulbi with ill-defined heterogeneously enhancing mass lesion in the posterior chamber of the left globe with subtle streakiness in the retroocular fat.
2. Focal mass lesions in the posterior chamber of the right globe along the superomedial (5 x 4 mm) and inferomedial (11 x 7 mm) aspect. No extraocular extension is seen.

Findings are suggestive of residual disease. Recommended: Clinical correlation and Comparison with previous scans.

Clinical correlation is necessary


DR. ANKUR GADODIA
MD (AIIMS), DNB, FRCR (UK)

This is a professional opinion and not the diagnosis. Findings should be clinically correlated.



डा. बी. आर. अम्बेडकर संस्थान रोटरी कैंसर अस्पताल
Dr. B.R. Ambedkar
 अ.भा.आ.सं.
 बहिरंग रो
 अस्पताल के अन्दर धुप्रप

R1-123495

11

OPR-6

DR. B.R.A. IRCH, AIIMS, NEW DELHI

IRCH No. 299366
 Clinic Radiotherapy Evaluation
 Deptt. RADIATION ONCOLOGY
 General

Reg. Date-04/07/2023

Clinic No. 2023-123495



UHID-106665953

एकक/Unit
 विभाग/Dept. **DR S Patry**
 नाम/Name

नाम रशमी रशमी
 Name RASHMI
 D/O- NEM PAL
 Phone No. 6396234342
 Address MIRZA PUR RANJIT BAHERI BAREILLY, UTTAR PRADESH,
 INDIA

Sex/Age F/3Y
 Room 5 (Shift Morning)

Date of Birth

निदान/Diagnosis

(L) EORB group E, (R) IORB (group C)

दिनांक/Date

04 JUL 2023

उपचार/Treatment

C/S/I RO-OPD & Patry. S. Patry -

3Y/F E (L) EORB & (R) group C IORB
 post 30 HD CEV & 10 RTT.

Plan: 40 HD CEV → (L) enucleation → (L) ext.

Adv:

- Pediatric oncology review (chemotherapy).
- RPC review (for surgery date; EUA).
- Review in RO-OPD & histopathology report

post enucleation on Tuesday / Friday
 at 8:30 AM.

रिजिस्ट्रार
 सहायक रिजिस्ट्रार
 रिनये आरक्षण कार्ड जारी किया
 Riv. Concession Issue DL
 07/07/23
 Dr. B.R.A. IRCH, AIIMS, New Delhi

[Signature]

अंगदान-जीवन का बहुमूल्य उपहार/ORGAN DONATION - A GIFT OF LIFE

O.R.B.O., AIIMS, 26588360, 26593444, www.orbo.org Helpline - 1060 (24 hrs service)

रोगियों के लिए धर्मशाला की सुविधा उपलब्ध है/Dharamshala facility is available for outstation patients